

Endodontics

Lec.2

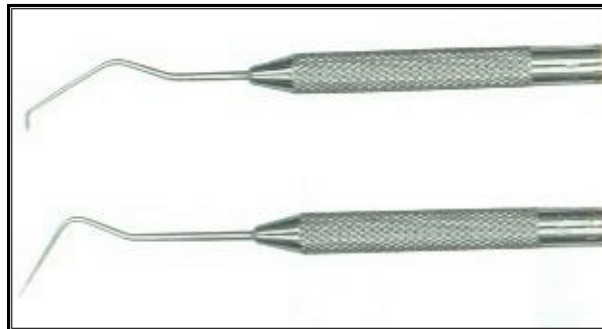
Dr. Jamal Aziz Mehdi

Basic instrumentation in Endodontics:-

It is now widely accepted that success in root canal treatment depends upon the thorough cleaning & shaping of the root canal system & the placement of a three- dimensional root canal filling of gutta-percha & inert sealer. To fulfill these objectives, many different instruments each with a specific purpose, must be available. Some of these instruments have been used for many years, whilst others are newer & highly technical.

❖ **Endodontic Explorer:-**

The straight end of the explorer is designed to aid in location of root canal orifices, its tip is sharp & able to negotiate a small opening, the instrument has sufficient rigidity to explore with controlled force. The L-shaped end aids in detection unremoved portions of the pulp chamber root.



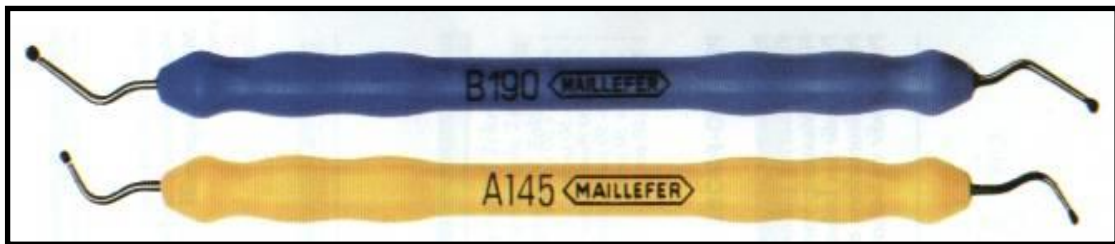❖ **Plastic Instrument:-**

The blade like end of this instrument is used to carry & place the temporary filling materials. The opposite end is used as a plugger to condense filling materials in the pulp chamber.




❖ **Endodontic excavator:-**

The shape of this instrument allows curettage of the pulp chamber when conventional excavator will not reach the floor of the chamber (had long shank). It's also part of the surgery kit and is used to curette periapical lesion.



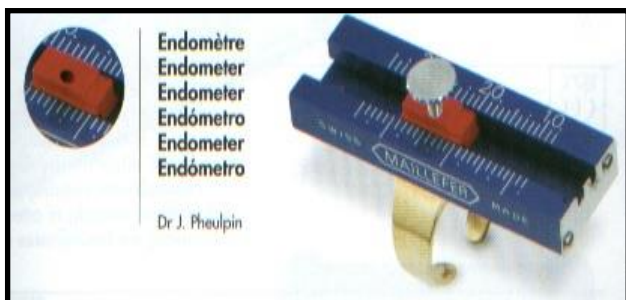❖ **Endodontic locking plier:-**

It has a latch that permits materials to be held without continuous finger pressure. The grooved tips facilitate holding absorbent points and gutta-percha cones, which tend to loosen in ungrooved tips.



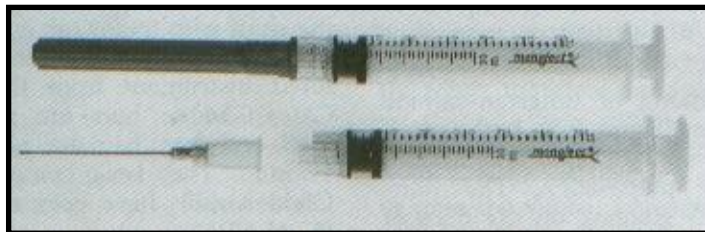❖ **Endodontic ruler:-**

The 0.5 mm ruler is a convenient instrument with which to measure files, gutta-percha cones, and also we have a measuring blocks and special millimeter thumb rulers.




❖ **Endodontic syringe:-**

It's used to carry the irrigants into the root canal. The needle tip is flat to prevent penetration into smaller canal diameter and grooved to allow irrigants that may be under pressure to flow coronally rather than be forced through the apical foramen. When drying canals, most of the irrigant may be aspirated from the canal by pulling back on the plunger.



❖ **Instrument organizer:-**

A means of organizing endodontic files according to size and length is a necessity. The organizer provides holes for the files, which are held vertically in a sponge allowing them to be grasped easily. The sponge is saturated with disinfectant solutions that maintain instrument sterility.




❖ **Transfer sponge:-**

A banker's sponge is a convenient aid to hold files during root canal preparation. As an assistant or the dentist adjusts the elastic stops on each file. The instruments are placed in the sponge according to size. Each file is then easily grasped, used and replaced in the sponge. The sponge, which is saturated with disinfectant solution, also is useful to debride the instrument. If, during canal preparation, debris and dentin shaving accumulate on the file, they are easily removed by inserting the file into the sponge a few minutes.



❖ Instrument stop:-

After the canal length is determined, it's necessary to mark that length on the file. This is accomplished by placing an elastic stop on the instrument shaft. Silicone stops are available commercially, or instrument stops can be made easily by cutting a rubber band into 2 mm squares, which are then centered on the instrument shaft.

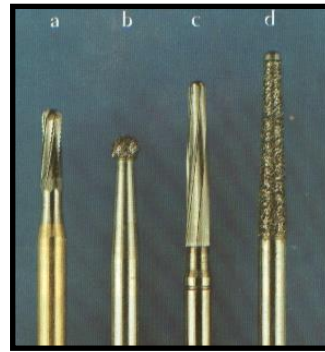
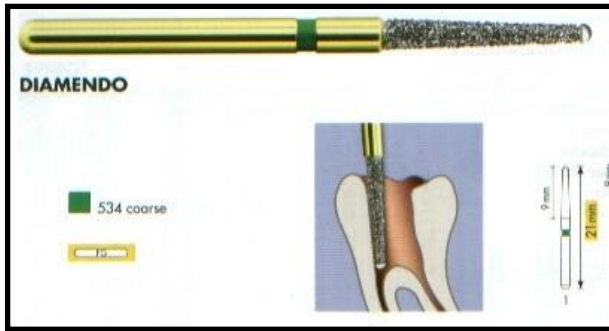


When placing the stop on the instrument, it's important to avoid angulation which may measure different lengths as the file is rotated. The test handle is an adjustable handle that can be moved on the instrument shaft and locked at a specific length. The assembly consists of a file shaft placed in a handle and nut. Once the correct length is set, the bulky handle provides a mechanical stop that prevents the instrument from extending beyond the measured length. For this reason, the test handle is useful to prevent unintentional instrumentation through the apical foramen.

❖ Burs:-

Several types of bur will be required to accomplish good access preparation.

1. **Round bur:** - round burs, normal and extra-long, size 2, 4, and 6, are used to lift the roof off the pulp chamber and eliminate over-hanging dentin. The longer and smaller sizes can be used to find calcified canals.
2. **Safe-ended burs:-** A safe-ended diamond or tungsten-carbide bur, the Endo-Z bur, both with a non-cutting tip, is used to taper & smooth the access cavity preparation. The non-cutting tip prevents gouging on the floor of the pulp chamber, where important landmarks could be lost in pinpointing the location of root canals.





❖ **Hand Spreader:-**

Manufactured from stainless steel, hand spreaders are designed to facilitate the placement of accessory gutta-percha points around a well-fitting master gutta-percha point during the lateral condensation method. Their diameter & shape are not standardized making it difficult to match spreaders with accessory gutta-percha points.

❖ **Finger spreaders:-**

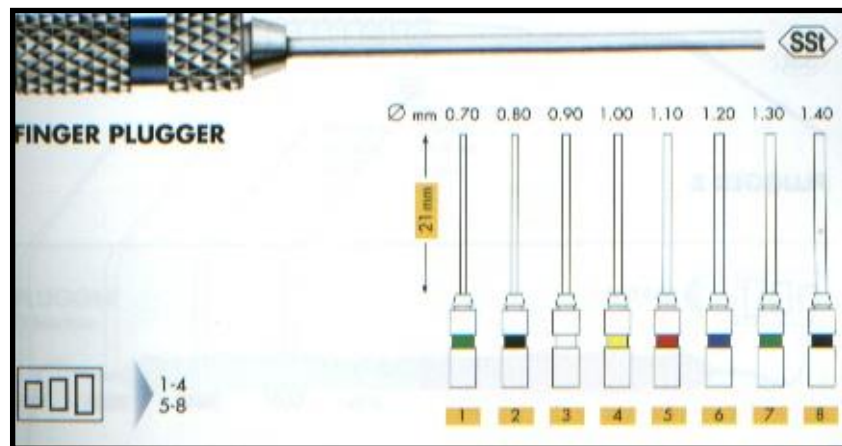
These instruments are color-coded to match either standardized or accessory gutta-percha points. Their short length affords a high degree of tactile sense & allows them to rotate freely around their axis, thus freeing the instrument for easy removal.

The depth of spreader penetration is important for the quality of the final apical seal; spreaders should be capable of reaching to within 1-2 mm of the apical stop alongside its master gutta-percha point.



Endodontic Pluggers:-

Endodontic pluggers consist of long-handled instruments which are of larger diameter than spreaders & have a blunt end; they are used to pack thermally softened gutta-percha into the root canal. The different-diameter pluggers have reference lines on the tips to allow the assessment of plugger depth. It's very important to realize when the plugger is engaging a cushion of softened gutta-percha, rather than the resistance of the canal wall. These pluggers may also be used to pack calcium hydroxide into root canals.



Thank You

Endodontics

Lec:3

Dr. Jamal Aziz Mehdi

Hand instruments

Hand instruments are grouped according to usage by the **International Organization for Standardization (ISO)**, working alongside the **American National Standards Institute (ANSI)**. These organizations have defined terminology, dimensions, physical properties, measuring systems and quality control of endodontic instruments and materials.

Standardization:-

The development of world wide standards for endodontic instruments and materials has occurred since the 1950s, when it was realized that a considerable amount of variation existed between root canal instruments of different manufacturers. At that time proposals for standardizing instruments were produced and covered the following:-

- 1) The diameter and taper of each instrument and filling point.
- 2) The graduated increase in size from one instrument to the next.
- 3) An instrument- numbering system based on the diameter of the instrument.

These proposals have been widely accepted, and endodontic hand instruments, (files, reamers and barbed broaches) are standardized in relation to size, color coding and physical properties.

The guidelines for instruments are:

1-Instruments are numbered from 06-150.Each number represent diameter of instrument in 100th of millimeter at the tip.

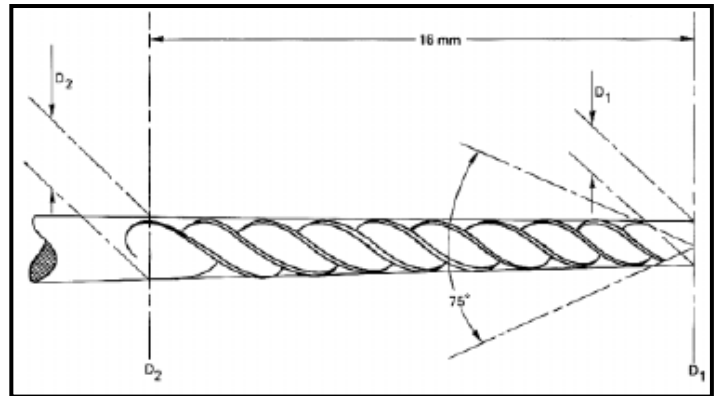
2-Working blade begins at tip (D_1) and extends 16 mm up the shaft (D_2). D_1 represents the diameter of the projection of the working part at the **tip end**, and is its nominal size. (D_2) is 0.32

mm greater than D_1 , ensuring that there is constant increase in taper, i.e 0.02mm per mm of instrument.

3-Tip angle of instrument varies as $75 \pm 15^\circ$.

4-Instrument handles are color coded for their easier recognition (yellow, red).

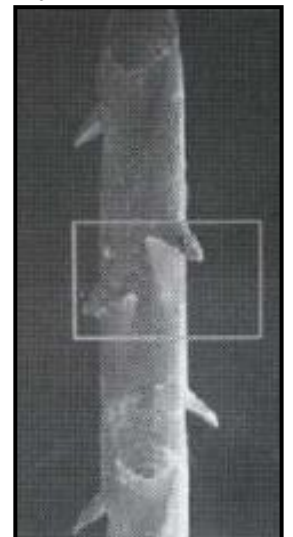
5-Instrument available in length 21, 25, 28, and 30mm are used for root canal therapy.



Barbed broaches:-

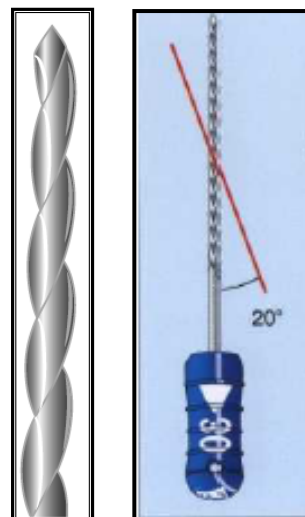
These are made from soft steel wire. The barbs are formed by cutting into the metal and forcing the cut portion away from the shaft, so that the tip of the barb points towards the handle. The cuts are made eccentrically around the shaft so that it's not weakened excessively at any one point. Barbed broaches are mainly used for the removal of pulp tissue from root canals, but also for removal of cotton- wool dressings.

Provided the instrument is loose within the canal and the barb is used to engage soft tissue only, the risk of fracture is minimal. However, as soon as the barbed broach is wedged against the wall of the canal, the barbs are flattened against the shaft. When an attempt is made to remove the instrument from the canal, the sharp barb tips dig into the canal wall and resist its withdrawal. Considerable force may be necessary to free the jammed instrument and there is a risk of either fracturing the shaft of the instrument or at least some of the individual delicate barbs. For this reason, the instrument should never be used to shape canal walls.



Reamers:-

Reamers are usually made from stainless steel by twisting tapered lengths of wire which have a triangular or square cross-section, to form an instrument with sharp cutting edges along the spiral. Although cross-section is a manufacturer's prerogative, the smaller sizes (15-50) are usually manufactured from a square blank, while the larger sizes are manufactured from a triangular blank. Reamers are used to enlarge and shape an irregularly shaped root canal into a cavity of round cross-section. The basic action is a half-turn twist and pull which shaves the canal, removing dentine chips from the root canal. However, anatomically, no root canal is round in cross-section and none can be prepared. Reamers are widely used in cleaning and shaping procedures, and during the method of canal preparation.



Files:-

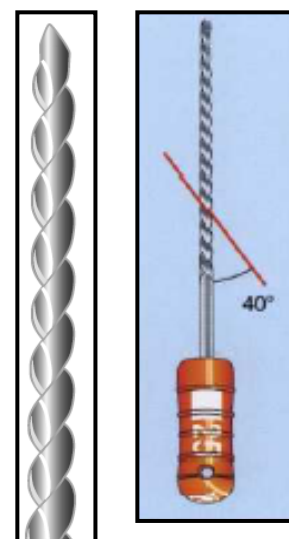
There are various types of root canal file, and they are usually made from stainless steel. The followings are the main types:-

1) K-file. 2) K-flex. 3) Flexofile. 4) Flex-R. 5) Hedstrom and Safety Hedstrom. 6) S-file.

Files are predominantly used with a filing or rasping action, in which there is little or no rotation of the instrument in the root canal, except for the Flex-R instrument.

K-file:-

This instrument is manufactured from stainless-steel wire which is ground into square or triangular cross-section. The blank is twisted into a tighter series of spirals than a reamer to produce from **0.9 to 1.9** cutting edges per millimeter length; some K-files are ground. When a K-file is manufactured from a



triangular cross-section it demonstrates **superior cutting efficiency**, and as a result of its increased **flexibility** is more likely to follow canal curvature than a file with a square cross-section.


K-flex file:-

The K-flex file has a cross-section that is **rhomboid-shaped** and the twisted instrument has a series of cutting flutes with alternate sharp ($< 60^\circ$) cutting edges and obtuse non-cutting edges. The cutting efficiency of the K-flex file is **greater** than many brands of K-file; due to its increased flexibility and ability to remove debris as its alternating blades provide a **reservoir** for debris, also the decrease in contact of instrument with canal walls provides more space for irrigation. A disadvantage of this file is its quicker loss of cutting efficiency.



Flexofile:-

This instrument is manufactured by maillefer in the same manner as the K-file but it has a **triangular cross-section** that gives sharper cutting blades and more room for debris than the conventional K-file. The stainless steel is extremely flexible and the instrument resists fracture. The **file tip is non-cutting (Butt)**.



A- K-file B- K-Flex file C- Flex-o-file

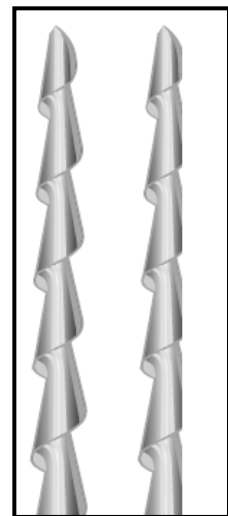
Flex-R file:-

Most root canal instruments have a sharp tip. Removal of the sharp cutting edges from the tip of the instrument helps to prevent undesirable ledge formation. The flex-R design eliminates the possibility of ledge formation by **removing the cutting surfaces at the tip's leading edge**. This enables the tip to ride along the canal rather than gouge into it. At the same time, the **triangular cross-sectional** area of the flex-R provides flexibility to negotiate severely curved canals.



Hedstrom and Safety Hedstrom:-

The hedstrom file is made by machining a steel blank of round cross-section to produce elevated cutting edges. The tapering effect appears to form a series of intersecting cones. Although the design leads to a flexible instrument, the instrument is inherently weak due to the small shaft diameter and is therefore prone to **breakage**. The hedstrom file has been reported to have a low cutting efficiency compared with other files as it only cuts on the withdrawal stroke, never the less it can be used to flare canal orifices and remove broken instruments, gutta-percha and silver points.



The safety hedstrom file (Kerr) features a non-cutting safety side along the length of the blade, which reduces the potential for strip perforations. The non-cutting side is oriented to the side

of the canal where cutting is not desired, and is indicated by a flattened side on the handle. The file is used with a traditional filing technique.

S-file (Unifile):-

Originally developed in Sweden, this instrument has an **S-shaped cross-section** which has been produced by grinding. This results in a stiffer instrument than the conventional Hedstrom file. A millimeter scale is etched onto the shaft of the instrument to facilitate length control. The instrument has good cutting efficiency in either a filing or reaming action; the instrument therefore could be classified as a hybrid design.



New instrument design and technology:-

Nickel-titanium file:-

In 1988, the properties of a file manufactured from **nickel-titanium (Ni-Ti) alloy** were reported. This file demonstrates greater elastic flexibility in bending, and greater resistance to torsional fracture than stainless steel. There are now several commercial versions. Ni-Ti files have a **non-cutting tip**, cannot be precurved, and tend to straighten curved root canals less than stainless steel file.

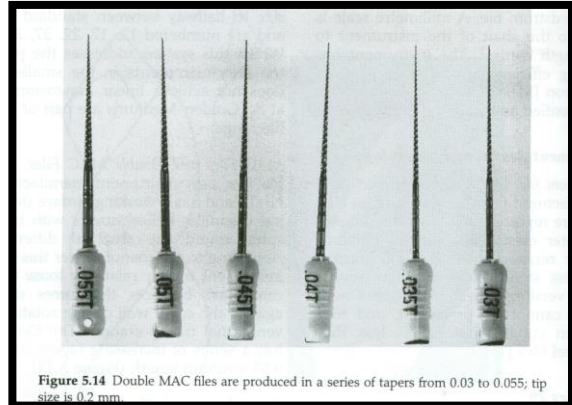


Golden-mediums:-

Maillefer have produced a series of **intermediate-size** instruments to complement ISO standard-size instruments. The new instruments roughly correspond in size to halfway between standard ISO sizes and are numbered 12, 17, 22, 27, 32, and 37. Whilst this system addresses the problem of two few instruments in the smaller sizes, it does not achieve linear dimensional change at D1. Golden-Mediums are part of the flexo-file range.

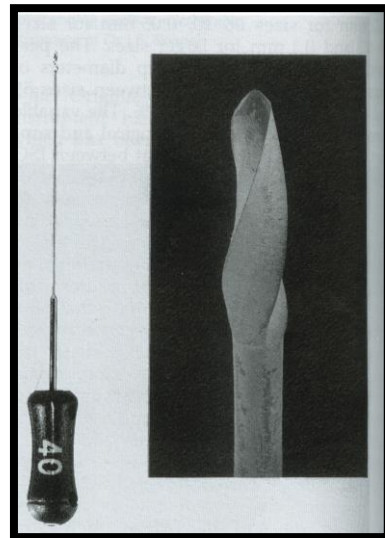
MAC files and Double MAC files:-

The MAC file is a new instrument manufactured from Ni-Ti, and has a working surface demonstrating dissimilar helical angles with blades that spiral round the shaft at different rates. According to the manufacturer this allows the instrument to stay relatively **loose** within the canal and balances the forces of the file against the canal wall during rotation to **prevent canal transportation**. The Double MAC has a series of increasing tapers from 0.03 to 0.55 mm/mm length.



Canal Master U:-

The Canal Master U (CMU) hand instrument was developed in the late 1980s. The instrument is used to prepare the **apical third of the canal**, and has a **non-cutting pilot tip**, a 1 mm length cutting blade, and a parallel sided shaft with a smaller diameter than the cutting blade. It's designed to improve debris removal and **reduce apically extruded debris**, further; it has been reported to create a well-centered canal preparation without ledging and transportation. Recently, a Ni-Ti CMU hand instrument has been developed, and it produces a better canal preparation than other files.



Flexogate:-

Similar in design and use to the CMU hand instrument, the flexogate is a logical development of the Gates-Glidden drill. Whereas the latter is used during conventional coronal preparation of the canal, the flexogate's task is enlarging the

apical region of the canal. The flexogate demonstrates a non-cutting guiding tip and debris evacuation zone which helps to maintain root canal configuration during instrumentation.

Whilst the flexogate can fracture more easily during torsion than the CMU, it has a breakage point approximately 16 mm from the tip, which ensures its retrieval in the event of separation. The bending moment of the flexogate and the CMU are well below standard's specifications for files, leading to considerable flexibility in curved canals.

Thank You

Endodontics

Lec: 4

Dr. Jamal Aziz Mehdi

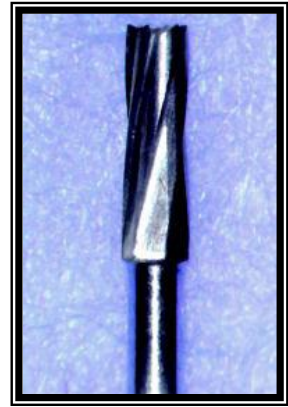
Access opening:

Endodontics cavity preparation may be separated into two anatomic divisions:-

a- Coronal preparation.

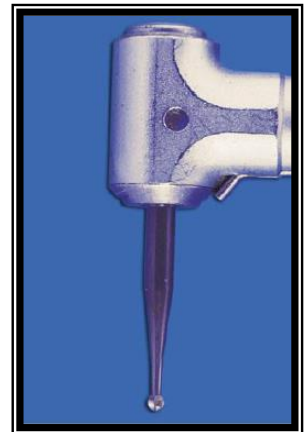Basic coronal instruments:-

1) The correct burs are mounted by the dental assistant prior to their use. Rarely should a bur have to be placed or changed during the operation. For initial entrance through the enamel surface or through a restoration, the ideal cutting instrument is the round

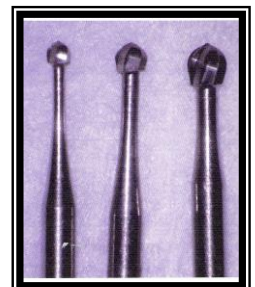


(carbide or diamond) bur or tapered fissure bur is used to penetrate through the enamel and slightly into the dentin (approximately 1mm). The high speed handpiece is used for its cutting efficiency.

2) As soon as the enamel or restorative penetration and minor surface extensions are complete, the accelerated handpiece is put aside, and the slow-speed (3.000 to 8.000 rpm) contra-angle handpiece is used, mounted with a round bur. Three sizes of round burs, No.s 2, 4, and 6, and two lengths, regular and surgical, are routinely used. The regular-length round bur in a conventional latch-type contra-angle handpiece will reach 9 mm from the nose of the contra-angle. The surgical-length bur will reach 14 or 15 mm and is necessary in some deep preparations.




3) The round burs are for dentin removal in both anterior and posterior teeth. These burs are first used to drill through the dentin and drop into the pulp chamber. The same bur is then employed in the removal of the roof at the pulp chamber. The choice of the size of the round



bur is made by estimating the canal width and chamber size and depth apparent in the initial radiograph.

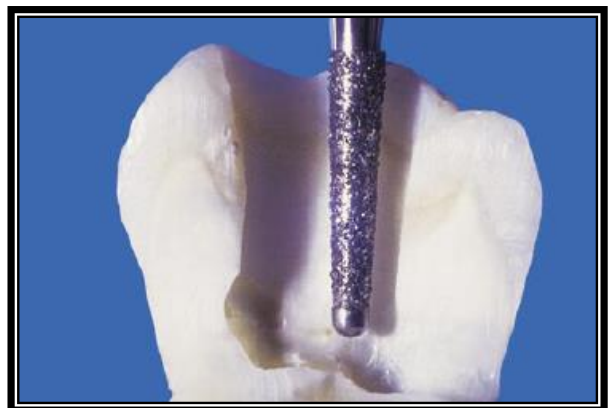
* The No. 2 round bur is generally used in preparing mandibular anterior teeth and most maxillary premolar teeth with narrow chambers and canals. It's also occasionally used in the incisal pulp horn area of maxillary anterior teeth. The No. 4 round bur is generally used in the maxillary anterior teeth and the mandibular premolar teeth. It's also occasionally used in young maxillary premolars and adult molars in both arches, that is, molars with extensive secondary dentin. The No. 6 round bur is used only in molars with large pulp chamber. A No. 1 round bur is also occasionally used in the floor of the pulp chamber to seek additional canal orifices.

- 4) As soon as the bulk of the overhanging dentin is removed from the roof of the chamber, the slower operating round burs are put aside, and once again, the high-speed fissure bur is used to finish and slope the side walls in the visible portions of the preparation. It's safe-ended and will not scar the pulpal floor. Moreover, it's longer bladed (9mm) for sloping and funneling the access cavity.

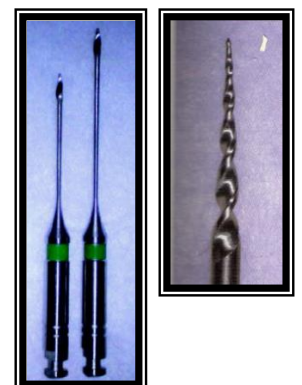


P.S.:- high-speed burs should not be used to penetrate into, or initially enlarge, the pulp chamber unless the operator is skilled in endodontic preparations.

In this operation, the clinician depends almost entirely on the "feel" of the bur deep inside the tooth, against the roof and walls of the pulp chamber, to judge the extensions that are necessary. High-speed equipment is operated by sight alone and is not generally employed in a blind area where reliance on tactile sensation is necessary.



- 5) Once the orifices have been located, they should be flared or enlarged and blended into the axial walls of the access cavity. This process permits the intracanal instruments used during shaping and cleaning to enter the canal(s) easily and effortlessly. Gates-Glidden burs can be used for this purpose, starting with smaller sizes



and progressing to the larger sizes. More recently, #.12 tapered rotary endodontic files have been used for the flaring.

Principles of endodontic cavity preparation:-

Any discussion of cavity preparation must ultimately revert to the basic principles of cavity preparation established by G.V. Black. Black's principles are therefore divided into the following:-

Endodontic coronal cavity preparation:-

- I- Outline form.
- II- Convenience form.
- III- Removal of the remaining carious dentin (and defective restorations).
- IV- Toilet of the cavity.

Endodontic Radicular cavity preparation:-

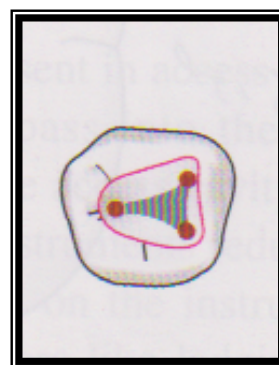
- I & II- Outline form and convenience form.
- III- Toilet of the cavity.
- IV- Retention form.
- V- Resistance form.

Principle I: Outline form

The outline form of the endodontic cavity must be correctly shaped and positioned to establish complete access for instrumentation, from cavity margin to apical foramen. Moreover, external outline form evolves from the internal anatomy of the tooth established by the pulp.

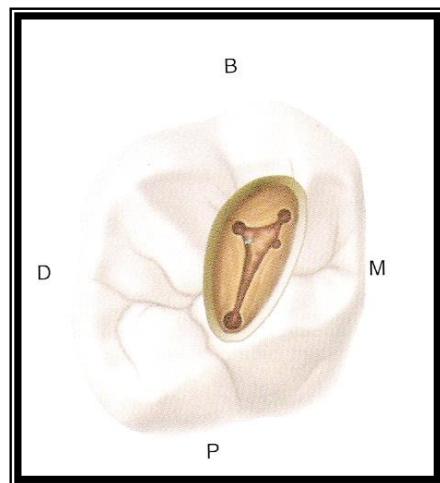
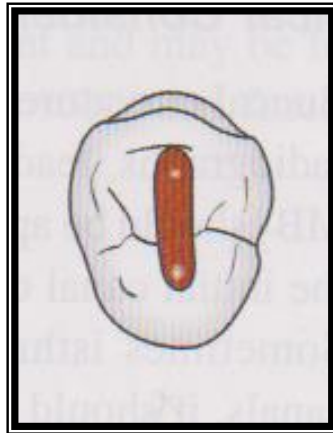
To achieve optimal preparation, three factors of internal anatomy must be considered:-

- 1) Size of the pulp chamber: - the outline form of endodontic access cavities is materially affected by the size of the pulp chamber. In young patients, these preparations must be more extensive than in older patients, in whom the pulp has receded and the pulp chamber is smaller in all three dimensions.
- 2) Shape of pulp chamber: - the finished outline form should accurately reflect the shape of the pulp chamber. For example, the floor of the pulp chamber in a molar tooth is usually triangular in shape, owing to the triangular position of the orifices of the canals. This triangular shape is extended up the walls of the cavity and out onto the occlusal surface,



hence, the final occlusal cavity outline form is generally triangular. As another example, the coronal pulp of a maxillary premolar is flat mesiodistally but is elongated buccolingually. The outline form is, therefore, an elongated oval that extends buccolingually rather than mesiodistally, as does Black's operative cavity preparation.

- 3) Number, position, and curvature of root canals:- this factor regulating outline form is the number, position, and curvature or direction of the root canals. To prepare each canal efficiently without interference, the cavity walls often have to be extended to allow an unstrained instrument approach to the apical foramen. When cavity walls are extended to improve instrumentation, the outline form is materially affected.

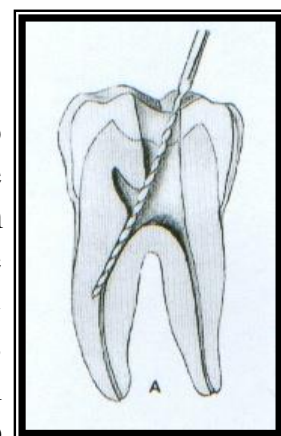


Principle II: - convenience form

Convenience form was conceived by Black as a modification of the cavity outline form to establish greater convenience in the placement of intracoronar restorations. In endodontic therapy, convenience form makes more convenient (and accurate) the preparation and filling of the root canals. Four important benefits are gained through convenience form modifications:-

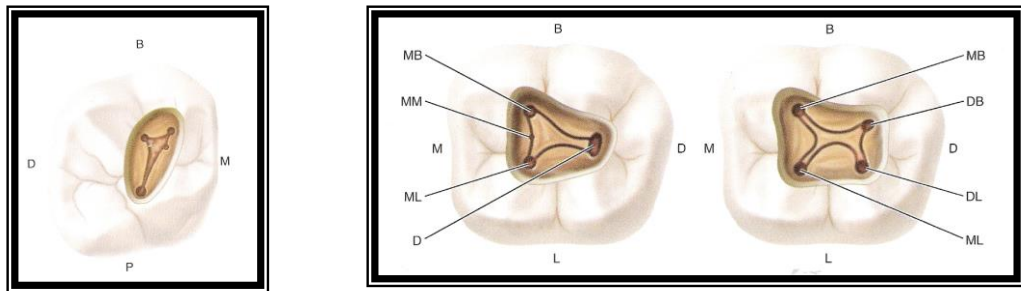
- 1- unobstructed access to the canal orifice:-

In endodontic cavity preparations of all teeth, enough tooth structure must be removed to allow instruments to be placed easily into the orifice of each canal without interference from overhanging walls. The clinician must be able to see each orifice and easily reach it with the instrument points. Failure to observe this principle not only endangers the successful outcome of the case but also adds materially to the duration of treatme



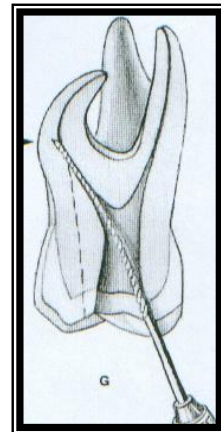
P.S.: Variations from the normal number of canals:-

- A) The lower incisors are a case in point. May have two canals; one labially and the other one lingually.
- B) High incidence of a second separate canal in the mesiobuccal root of maxillary molars.
- C) A second canal often is found in the distal root of mandibular molars as well.
- D) The premolars, both maxillary and mandibular, can also be counted on to have extra canals.



2- direct access to the apical foramen:-

To provide direct access to the apical foramen, enough tooth structure must be removed to allow the endodontic instruments freedom within the coronal cavity so they can extend down the canal in an unstrained position. This is especially true when the canal is severely curved or leaves the chamber at an obtuse angle.



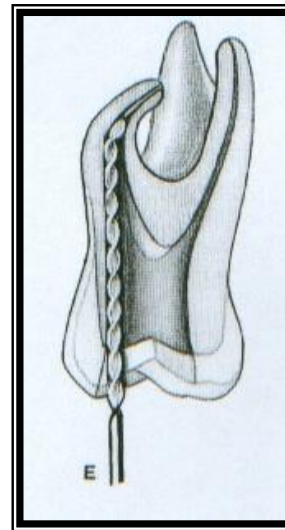
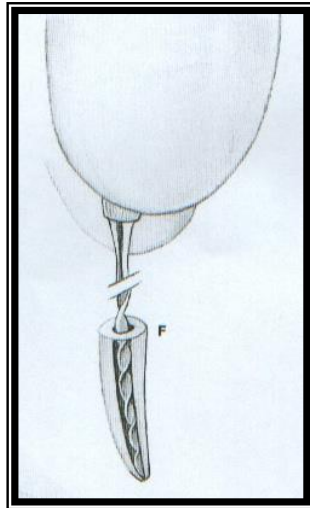
3- Extension to accommodate filling techniques:-

It's often necessary to expand the outline form to make certain filling techniques more convenient or practical. If a softened gutta-percha technique is used for filling, where in rather rigid pluggers are used in a vertical thrust, then the outline form may have to be widely extended to accommodate these heavier instruments.

4- Complete authority over the enlarging instrument:-

It's imperative that the clinician maintain complete control over the root canal instrument. If the instrument is impinged at the canal orifice by tooth structure that should have been removed, the dentist will have lost control of the direction of the tip of the instrument, and the intervening tooth structure will dictate the control of the instrument. If, on the other hand, the tooth structure

is removed around the orifice so that the instrument stands free in this area of the canal, the instrument will then be controlled by only two factors; the clinician's fingers on the handle of the instrument and the walls of the canal at the tip of the instrument. Nothing is to intervene between these two points.

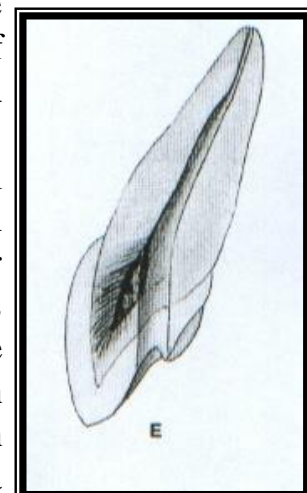


Principle III: - removal of the remaining carious dentin and defective restorations

Caries and defective restorations remaining in an endodontic cavity preparation must be removed for three reasons:-

- 1) To eliminate mechanically as many bacteria as possible from the interior of the tooth.
- 2) To eliminate the discolored tooth structure, that may ultimately lead to staining of the crown.
- 3) To eliminate the possibility of any bacteria-laden saliva leaking into the prepared cavity. The last point is especially true of proximal or buccal caries that extend into the prepared cavity.

If the caries is so extensive that the lateral walls are destroyed, or if a defective restoration is in place that is loose and leaking, then the entire wall or restoration should be removed and later restored. It's important that restoration be postponed until the radicular preparation has been completed. It's much easier to complete the Radicular preparation through an open cavity than through a restored crown. As a



matter of fact, the more crown that is missing, the easier the radicular preparation becomes. The ultimate in ease of operation is the molar tooth broken off at the gingival level.

Principle IV: - toilet of the cavity

All of the caries, debris, and necrotic material must be removed from the chamber before the radicular preparation is begun. If the calcified or metallic debris is left in the chamber and carried into the canal, it may act as an obstruction during canal enlargement. Soft debris carried from the chamber might increase the bacterial population in the canal. Coronal debris may also stain the crown, particularly in anterior teeth.

Round burs, of course, are most helpful in cavity toilet. The long-blade, endodontic spoon excavator is ideal for debris removal. Irrigation with sodium hypochlorite is also an excellent measure for cleaning the chamber and canals of persistent debris.

The chamber may finally be wiped out with cotton, and a careful flush of air will eliminate the remaining debris. However, air must never be aimed down the canals. Emphysema of the oral tissues has been produced by a blast of air escaping out of the apex.

Thank you

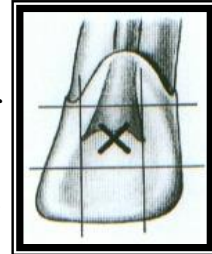
Endodontics

Lec:5

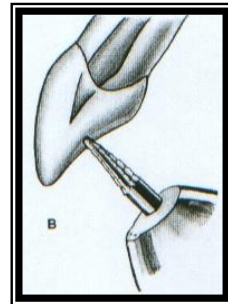
Dr. Jamal Aziz Mehdi

Access opening of anterior teeth:-

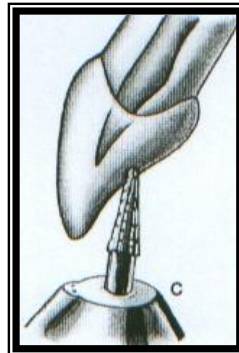
A- Entrance is always gained through the lingual surface of all anterior teeth. Initial penetration is made in the exact center of the lingual surface at the position marked "X". A common error is to begin the cavity too far gingivally.



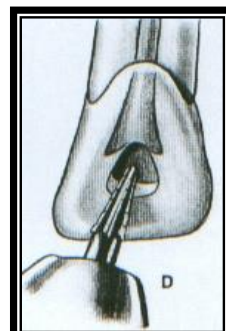
B- Initial entrance is prepared with a round-point tapering fissure bur (or round bur) in an accelerated-speed contra-angle handpiece with water coolant, operated at a right angle to the long axis of the tooth. Only enamel is penetrated at this time. Do not force the bur; allow it to cut its own way.



C- Convenience extension toward the incisal continues the initial penetrating cavity preparation. Maintain the point of the bur in the central cavity and rotate the handpiece toward the incisal so that the bur parallels the long axis of the tooth. Enamel and dentin are beveled toward the incisal. Entrance into the pulp chamber should not be made with an accelerated-speed instrument. Lack of tactile sensation with these instruments precludes their use inside the tooth.




D- The preliminary cavity outline is funneled and fanned incisally with a fissure bur.




Enamel has a short bevel toward the incisal, and a "nest" is prepared in the dentin to receive the round bur to be used for penetration.

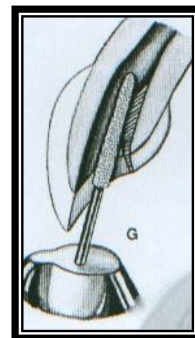
- E- A surgical length No.2 or 4 round burs in a slow-speed contra-angle handpiece is used to penetrate the pulp chamber. If the pulp has greatly receded, a No.2 round bur is used for initial penetration. Take advantage of convenience extension toward the incisal to allow for the shaft of the penetrating bur, operated nearly parallel to the long axis of the tooth.



- F- Once the pulp chamber has been penetrated, the remaining roof is removed by catching the end of a round bur under the lip of the dentine roof and cutting on the burs withdrawal stroke (Working from inside the chamber to outside).

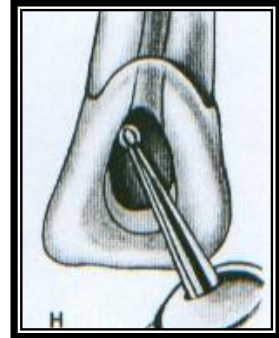


- G- Once the orifice(s) has been identified and confirmed, the lingual shoulder is removed. This is the lingual shelf of dentin that extends from the cingulum to a point approximately 2mm apical to the orifice. The lingual shoulder can be removed with a tapered safety-tip diamond or carbide bur. The tip of a fine safety-tip diamond bur is placed approximately 2mm apical to the canal orifice and inclined to the lingual during rotation to slope the lingual shoulder. The clinician must be careful when using this bur to avoid placing a bevel on the incisal edge. The lingual "shoulder" is removed to give continuous, smooth-flowing preparation.




- H- Occasionally, a No.1 or 2 round bur must be used laterally and incisally to eliminate pulpal horn debris and bacteria, this also prevents future discoloration.

I- Final preparation relates to the internal anatomy of the chamber and canal. In a "young" tooth with a large pulp, the outline form reflects a large triangular internal anatomy- an extensive cavity that allows thorough cleansing of the chamber as well as passage of large instruments and filling materials needed to prepare and fill a large canal. Cavity extension toward the incisal allows greater access to the midline of the canal.

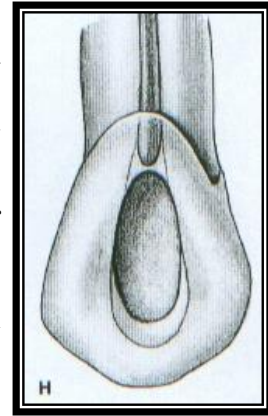


J- Cavity preparations in "adult" teeth, with the chamber obturated with secondary dentin, are ovoid in shape. Preparation funnels down to the orifice of the canal. The further the pulp has receded, the more difficult it is to reach to this depth with a round bur. Therefore, when the radiograph reveals advanced pulpal recession, convenience extension must be advanced further incisally to allow the bur shaft and instruments to operate in the central axis.

K- Final preparation with the reamer in place, the instrument shaft clears the incisal cavity margin and reduced lingual "shoulder", allowing an unrestrained approach to the apical third of the canal. The instrument remains under the optimal, round, tapered cavity may be prepared in the apical third, tailored to the requirements of round, tapered filling materials to follow. The remaining ovoid part of the canal is cleaned and shaped by circumferential filling or Gates-Glidden drills.

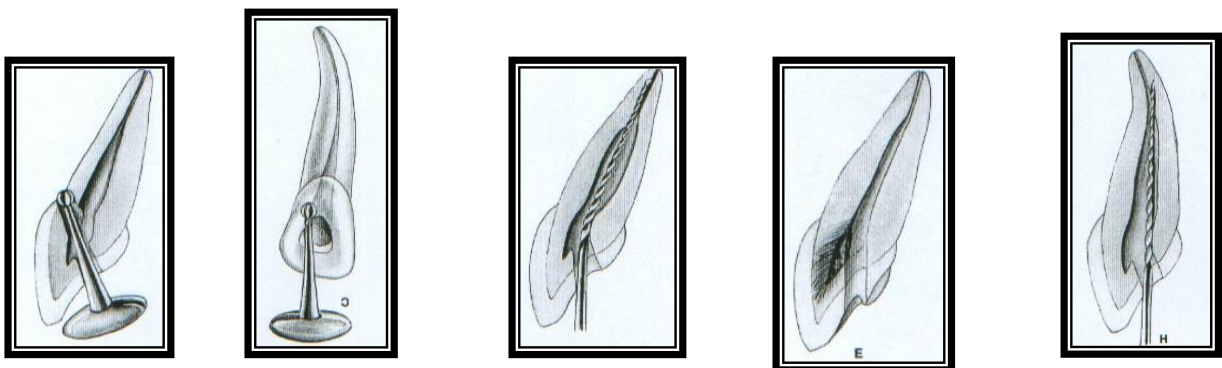


P.S.:- In Maxillary canine, extensive, ovoid, funnel-shaped preparation must be nearly as large as for a young tooth. A beveled incisal extension carries preparation nearer the central axis, allowing better access to the curved apical third. Discovery by exploration of an apical labial curve calls for even greater incisal extension.



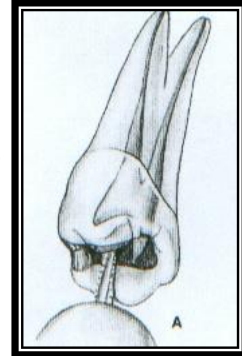
Errors in cavity preparation:-

- 1) Perforation at the labiocervical caused by failure to complete convenience extension toward the incisal, prior to the entrance of the shaft of the bur.
- 2) Gouging of the labial or distal wall caused by failure to recognize the lingual- axial or mesial-axial inclination of the tooth.
- 3) Pear-shaped preparation of the apical canal caused by failure to complete convenience extensions. The shaft of the instrument rides on the cavity margin and lingual "shoulder". In adequate debridement and obturation ensure failure.
- 4) Discoloration of the crown caused by failure to remove pulp debris. The access cavity is too far to the gingival with no incisal extension.
- 5) Ledge formation at the apical-labial curve caused by failure to complete the convenience extension. The shaft of the instrument rides on the cavity margin and "shoulder".

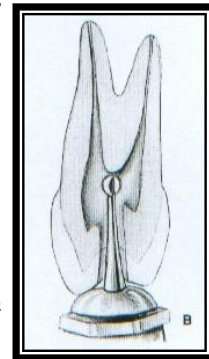


Access opening of premolar teeth:-

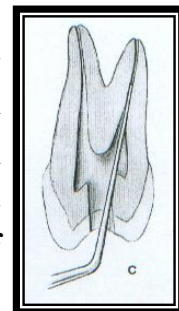
A- Entrance is always gained through the occlusal surface at all posterior teeth. Initial penetration is made parallel to the long axis of the tooth in the exact center of the central groove between the cusp tips of the maxillary premolars. In mandibular first premolars the starting location is halfway up the lingual incline of the buccal cusp on a line connecting the cusp tips mandibular second premolars require less of an adjustment because they have less lingual inclination.



B- A regular-length No.2 or 4 round bur is used to open into the pulp chamber. The bur will be felt to "drop" when the pulp chamber is reached. If the chamber is well calcified and the "drop" is not felt, vertical penetration is made until the contra-angle handpiece rests against the occlusal surface. This depth is approximately 9mm, the position of the floor of the pulp chamber that lies at the cervical level. In removing the bur, the orifice is widened buccolingually to twice the width of the bur to allow room for exploration for canal orifices. If a surgical-length bur is used, care must be exercised not to perforate the furca.

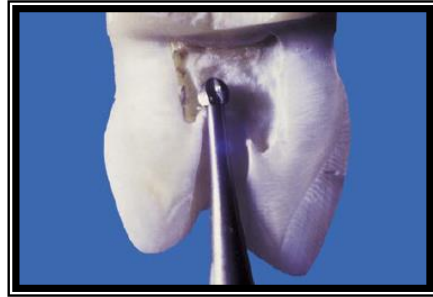


C- An endodontic explorer is used to locate orifices to the buccal and lingual canals in the first premolar or the central canal in the second premolar. Tension of the explorer shaft against the walls of preparation will indicate the amount and

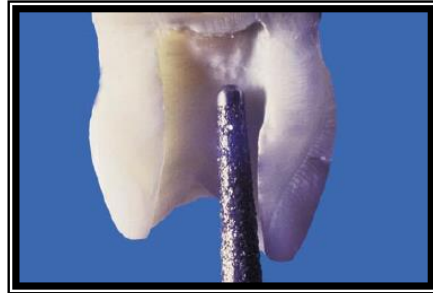

direction of extension necessary.

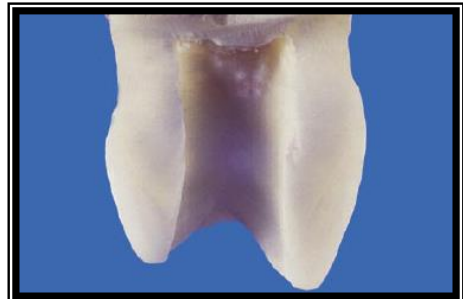
D- Working from inside the pulp chamber to outside, a round bur is used at low speed to extend the cavity buccolingually by removing the roof of the pulp chamber.



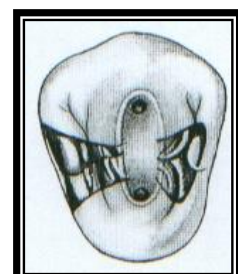
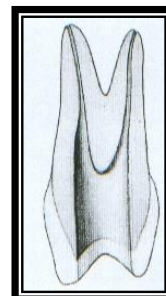
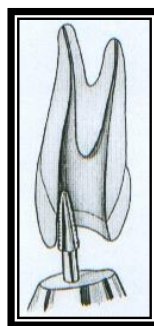
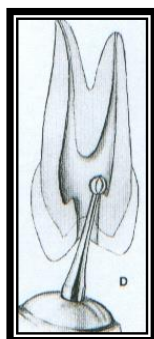
E- Buccolingual extension and finish of cavity walls are completed with a 701U fissure bur at accelerated speed.



F-Final preparation should provide unobstructed access to canal orifices. Cavity walls should not impede complete authority over enlarging instruments.



G-Outline form of final preparation will be identical for both newly erupted and "adult" teeth. Buccolingual ovoid preparation reflects the anatomy of the pulp chamber and the position of the buccal and lingual canal orifices. The cavity must be extensive enough to allow for instruments and filling materials needed to enlarge and fill canals. Further exploration at this time is imperative. It may reveal the orifice to an additional canal, a second canal in the second premolar, or a third canal in the first premolar.



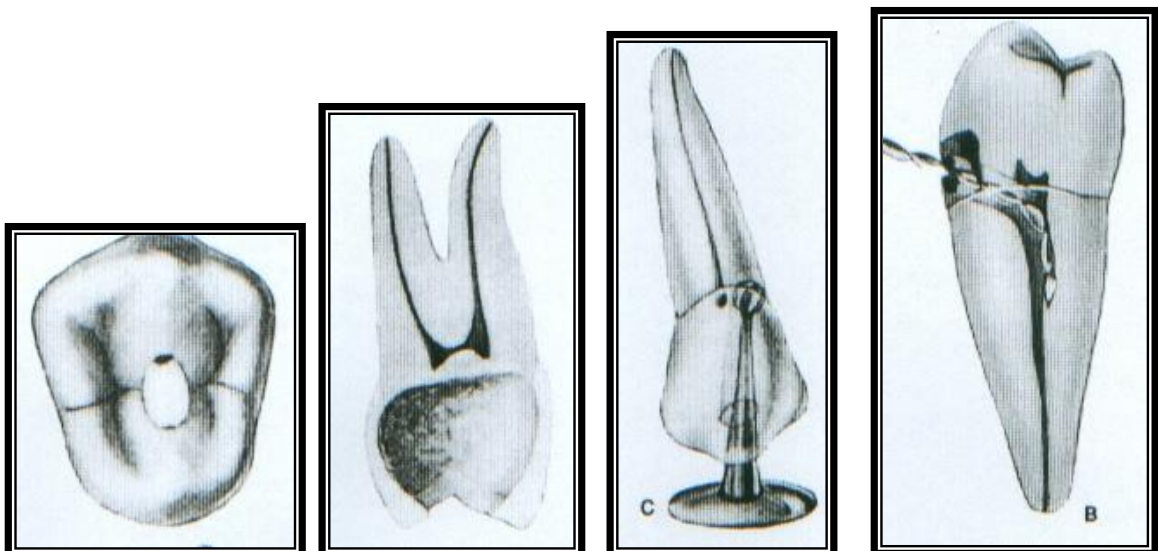
Mandibular Premolars:

*-slight variations exist between mandibular and maxillary premolars because of the lingual tilt of mandibular premolars.

*the access cavity in these teeth should have extended on to the buccal cusp tip, in order to gain straight line access.

Errors in cavity preparation:-

- 1) Under extended preparation exposing only pulp horns. Control of enlarging instruments is abdicated to cavity walls. The white color of the roof of the chamber is a clue to a shallow cavity.
- 2) Over extended preparation from a fruitless search for a receded pulp. The enamel walls have been completely undermined. Gouging relates to failure to refer to the radiograph, which clearly indicates pulp recession.
- 3) Perforation at the mesiocervical indentation. Failure to observe the distal-axial indentation of the tooth led to bypassing receded pulp and perforation. The maxillary first premolar is one of the most commonly perforated teeth.
- 4) Incomplete preparation and possible instrument breakage caused by total loss of instrument control. Use only occlusal access, never buccal or proximal access.



Average length of all permanent teeth

Teeth	Average Length	Canals	%	Root Curvature	%
Upper Centrals	23 mm	One canal	100%	Straight	75%
Upper Laterals	22.8 mm	One canal	100%	Distal Curvature	53%
				Straight	30%
Upper Canines	26 mm	One Canal	100%	Distal Curvature	32%
				Straight	39%
Lower Centrals	21.5 mm	One canal/One foramen	70%	Distal Curvature	23%
		Two canals/One foramen	23%	Straight	60%
Lower Laterals	22.4 mm	One canal/One foramen	57%	Distal Curvature	23%
		Two canals/Two foramen	30%	Straight	60%
Lower Canines	25 mm	One canal	94%	Distal Curvature	20%
				Straight	68%
Upper Fours	21.8 mm	Two canals/Two foramina	72%	Distal Curvature	37%
		Two canals/One foramen	13%	Straight	38%
Upper Fives	21%	One canal/One foramen	75%	Distal Curvature	27%
		Two canals/Two foramina	20%	Buccal Curvature	12.7%
				Bayonet Curvature	20.6%
Lower Fours	22 mm	One canal/One foramen	73.5%	Distal Curvature	35%
		Two canals/Two foramina	19.5%	Straight	48%
Lower Fives	21.4 mm	One canal/One foramen	85.5%	Distal Curvature	40%
		Two canals/Two foramina	11.5%	Straight	39%

Endodontics

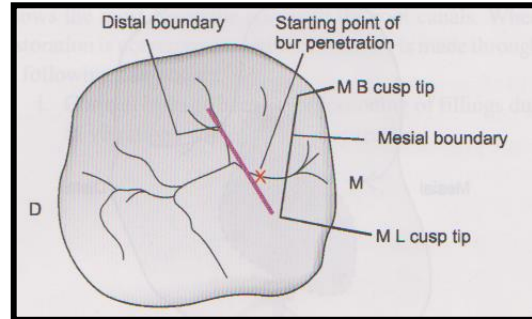
Lec.6

Dr. Jamal Aziz Mehdi

Access opening of posterior teeth:-

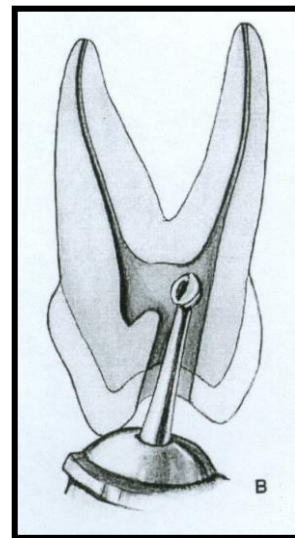
❖ Maxillary molar teeth:-

A- Entrance is always gained through the occlusal surface of all posterior teeth. Initial penetration is made in the exact center of the mesial pit, with the bur directed toward the lingual.

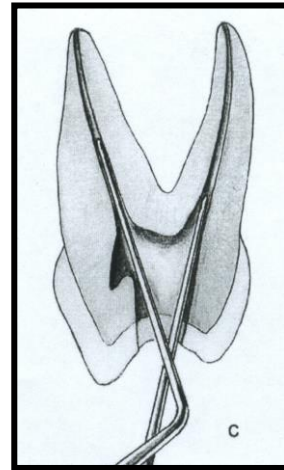


The 702 U tapering fissure bur in an accelerated-speed contra-angle handpiece is ideal for perforating gold casting or virgin enamel surface to the depth of dentin. Amalgam fillings are penetrated with a No.4 or 6 round bur operating in a slow-speed contra-angle handpiece.

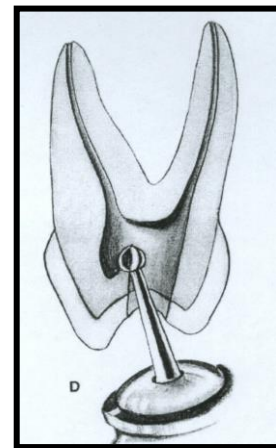
B- According to the size of the chamber, a regular-length No.4 round bur is used to open into the pulp chamber. The bur should be directed toward the orifice of the palatal canal or toward the mesiobuccal canal orifice, where the greatest space in the chamber exists. It will be felt to "drop" when the pulp chamber is reached. If the chamber is well calcified, initial penetration is continued until the contra-angle rests against the occlusal surface. This depth of 9mm is the usual position of the floor of the pulp chamber, which lies at the cervical level. Working from inside out, back toward the buccal, the bur removes enough roof of the pulp chamber for exploration.




C- An endodontic explorer is used to locate orifices of the palatal, mesiobuccal, and distobuccal canals. Tension of the explorer against the walls of preparation will indicate the amount and direction of extension necessary. Orifices of canals form the perimeter of preparation. Special care must be taken to explore for a second canal in the mesiobuccal root.



D- Again, working at slow speed from inside to outside, a round bur is used to remove the roof of the pulp chamber. Internal walls and floor of preparation should not be cut into unless difficulty is encountered in locating orifices. In that case, surgical-length No.2 round burs are necessary to explore the floor of the chamber. Internally, the access cavity

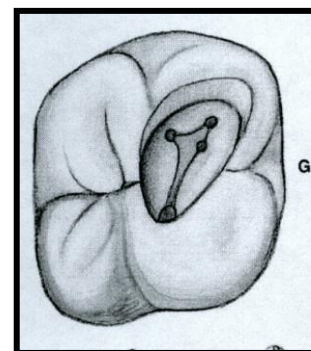
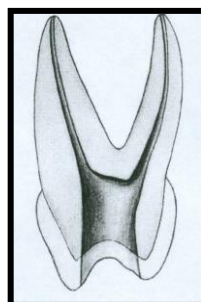
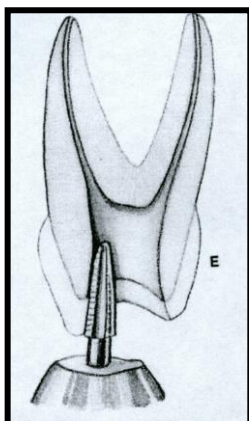


should have all orifices positioned entirely on the pulp floor and should not extend into an axial wall. Extension of an orifice into the



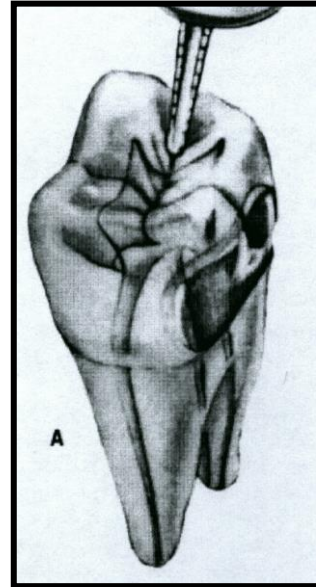
axial wall creates a mouse hole effect, which indicates internal underextension and impedes straight-line access. In such cases the orifice must be repositioned onto the pulp floor without interference from the axial

- E- In posterior teeth the internal impediments are the cervical dentine bulges and natural coronal canal constriction. The cervical bulges are shelves of dentin that frequently overhang orifices in posterior teeth, restricting access into root canals. These bulges can be removed with safety tip diamond or carbide burs. Final finish and funneling of cavity walls are completed with a 702U fissure bur or tapered diamond points at accelerated speed.
- F- Final preparation provides unobstructed access to canal orifices and should not impede complete authority of enlarging instruments. Improve ease of access by "leaning" the entire preparation toward the buccal, for all instrumentation is introduced from the buccal. Notice that the preparation extends almost to the length at the buccal cusps. The walls are perfectly smooth, and the orifices are located at the exact pulpal-axial angles of the cavity floor.
- G- Extended outline form reflects the anatomy of the pulp chamber. The base is towards the buccal and the apex is to the lingual, with the canal orifice positioned at each angle of the triangle. The cavity is entirely within the mesial half of the tooth and need not invade the transverse ridge but is extensive enough, buccal to lingual, to allow positioning of instruments and filling materials. Outline form of final preparation is identical for both a newly erupted and an "adult" tooth. Note the orifice to the fourth canal. Internally, the access cavity should have all orifices positioned entirely on the pulp floor and should not extend into an axial wall. Extension of an orifice into the axial wall creates a mose hole effect, which indicates internal underextension and impedes straight-line access. In such cases the orifice must be repositioned onto the pulp floor without interference from the axial.

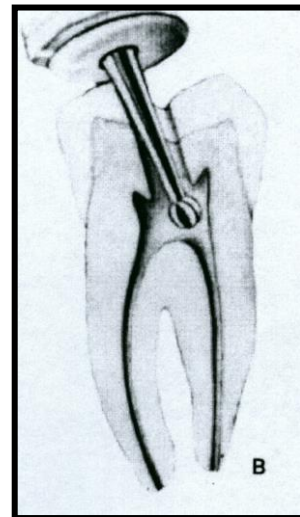


❖ Mandibular molar teeth:-

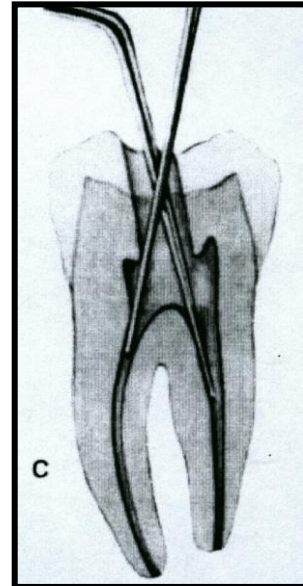
A- Entrance is always gained through the occlusal surface of all posterior teeth. Initial penetration is made in the exact center of the mesial pit, with the bur directed toward the distal. The 702U tapering fissure bur is in an accelerated-speed contra-angle handpiece is ideal for perforating gold casting or virgin enamel surface to the depth of dentin. Amalgam fillings are penetrated with a No.4 round bur operating in a high-speed contra-angle handpiece.



B- According to the size of the chamber, a regular-length No.4 or 6 round bur is used to open into the pulp chamber. The bur should be directed toward the orifice of the mesiobuccal or distal canal, where the greatest space in the chamber exists. It will be felt to "drop" when the pulp chamber is reached. If the chamber is well calcified, initial penetration is continued until the contra-angle handpiece rests against the occlusal surface. This depth of 9mm is the usual position of the floor of the chamber, which lies at the cervical level. Working from inside out, back toward the mesial, the bur removes enough roof of the pulp chamber for exploration.

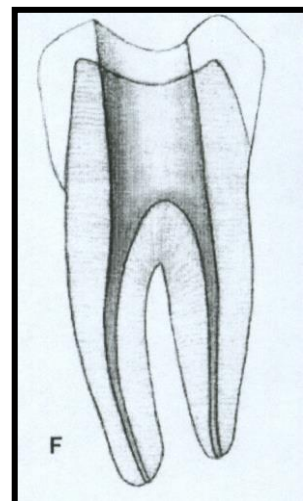
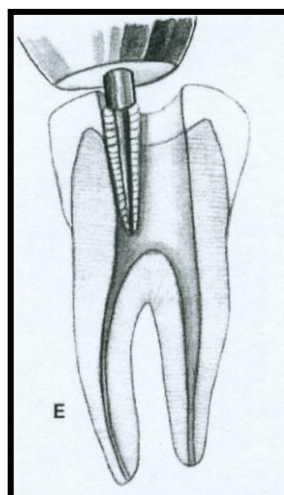
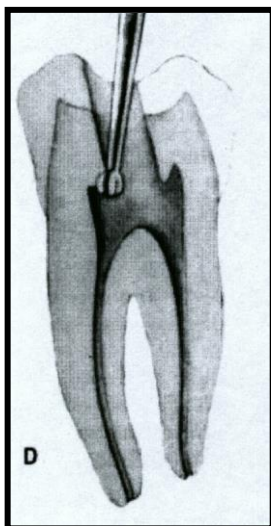


C- An endodontic explorer is used to locate orifices of the distal, mesiobuccal, and mesiolingual canals. Tension of the explorer against the walls of preparation indicates the amount and direction of extension necessary. Orifices of the canals form the perimeter of preparation. Special care must be taken to explore for an additional canal in the distal root. The distal canal should form a triangle with two mesial canals. If it is asymmetric, always look for the fourth canal 29% of the time.



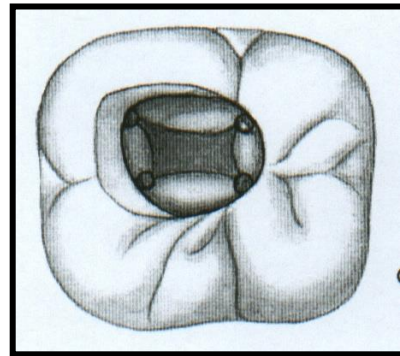
D- Again, working at slow speed from the inside to outside, a round bur is used to remove the roof of the pulp chamber. Internal walls and floor of preparation should not be cut into unless difficulty is encountered in locating orifices. In that case, surgical-length no.2 or 4 round burs are necessary to explore the floor of the chamber.

E- Final finish and funneling of cavity walls are completed with a 702U fissure bur or diamond point at accelerated speed.



F- Final preparation provides unobstructed access to canal orifices and should not impede the complete authority of enlarging instruments. Improve ease of access by "leaning" the entire preparation toward the mesial, for all instrumentation is introduced from the mesial. Notice that the cavity outline extends to the height of the mesial cusps. The walls are perfectly smooth and the orifice located at the exact pulpal-axial angle of the cavity floor.

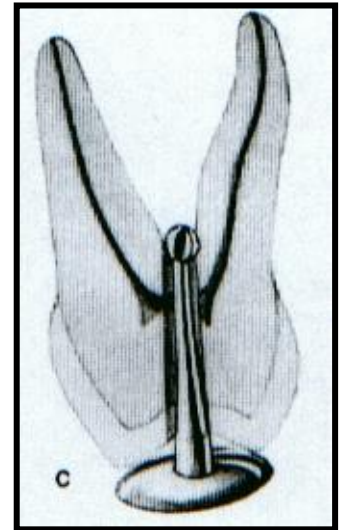
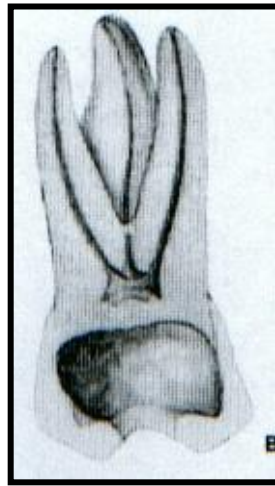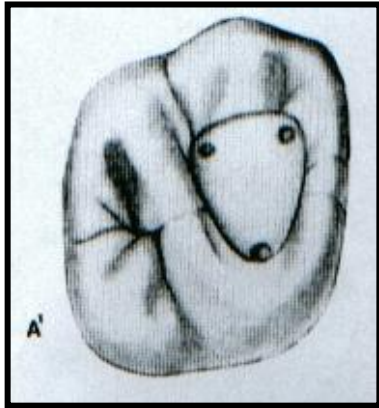
G- "Square" outline form reflects the anatomy of the pulp chamber. Both mesial and distal walls slope mesially. The cavity is primarily within the mesial half of the tooth but is extensive enough to allow positioning of the instrument and filling materials. The outline form of the final preparation will be identical for both a newly erupted and an "adult" tooth. Further exploration should determine if a fourth canal can be found in the distal root. If so, the outline is extended in that direction. In that case, an orifice will be positioned at each angle of the square.



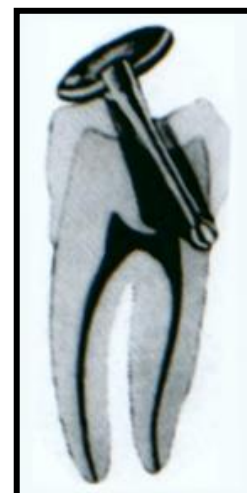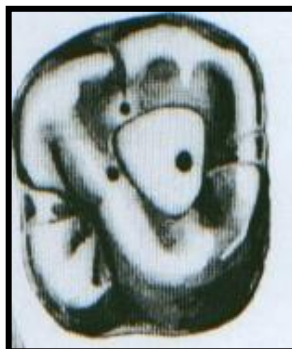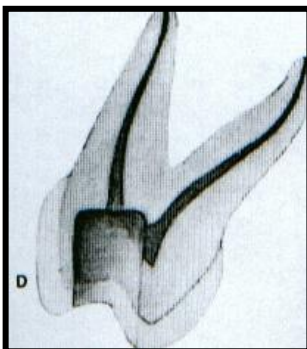
Errors in cavity preparation of posterior teeth:-

- 1) Under extended preparation. Pulp horns have merely been "nicked" and the entire roof of the pulp chamber remains. "White" color dentin of the roof is a clue to under extension.
- 2) Over extended preparation undermining enamel walls. The crown is badly gouged owing to failure to observe pulp recession in the radiograph.
- 3) Perforation into furca using a surgical-length bur and failing to realize that the narrow pup chamber had been passed. Operator error in failure to

compare the length of the bur to the depth of the pulp canal floor. Length should be marked on the bur shank with dycal.



- 4) Inadequate vertical preparation related to failure to recognize severe buccal inclination of an unopposed molar.
- 5) Disoriented occlusal outline form exposing only the palatal canal. A faulty cavity has been prepared in full crown, which was placed to "straighten" a rotated molar. Palpating for mesiobuccal root prominence would reveal the severity of the rotation.
- 6) Perforation at the wall cavity caused by failure to orient the bur with the long axis of the molar severely tipped to the mesial.



Average length of all posterior permanent teeth

Teeth	Canals	Average Length	Canals	%	Canals in mesiobuccal root	%
Upper First Molars	Mesiobuccal	20 mm	3 Canals	41%	One canal/one foramen	41%
	Distobuccal	19.4 mm	4 Canals	56.5%	Two canals/one foramen	40%
	Palatal	20.6 mm			Two canals/two foramina	19%
Upper Second Molars	Mesiobuccal	20 mm	Fused	46%	One canal/one foramen	63%
	Distobuccal	19.4 mm			Two canals/one foramen	13%
	Palatal	20.8 mm	3 Canals	54%	Two canals/two foramina	24%
Lower First Molars	Mesial	20.9 mm	3 Canals	64.4%	Two canals/one foramen	40%
					Two canals/two foramina	60%
	Distal	20.9 mm	4 Canals	29%	One canal	71%
Lower Second Molars	Mesial	20.9 mm	2 Canals	60%	Two canals	29%
					One canal/one foramen	13%
					Two canals/one foramen	49%
	Distal	20.8 mm	3 Canals	30%	Two canals/two foramina	38%
					One canal/one foramen	92%
					Two canals/one foramen	5%
					Two canals/two foramina	3%

Endodontics

Lec:7

Dr. Jamal Aziz Mehdi

Determination of working length

Exploration for the canal orifice:-

Before the canals can be entered, their orifices must be found. In older patients, finding a canal orifice may be the most difficult and time consuming operation. The endodontic explorer is the greatest aid in finding a minute canal entrance, feeling along the walls and into the floor of the chamber in the area where the orifices are expected to be. Extension of the walls toward these points forms the basic perimeter of the preparation. When we find the orifices, we start to negotiate with small size instrument ex: size 15 to be sure that the canal is patent till the apex. Start extirpation with barbed broach, using the proper size according to the size of the canal. The barbed broach should be loose (no engagement of dentin during rotation).

Technique of pulp extirpation:

- 1-Penetrates the barbed broach along the canal wall towards the apex.
- 2-As it reaches to the apical constriction, move it into the center of mass of pulp tissue
- 3-Rotate the broach several times in a watch winding manner to entrap the pulp which is then withdrawn from the canal.

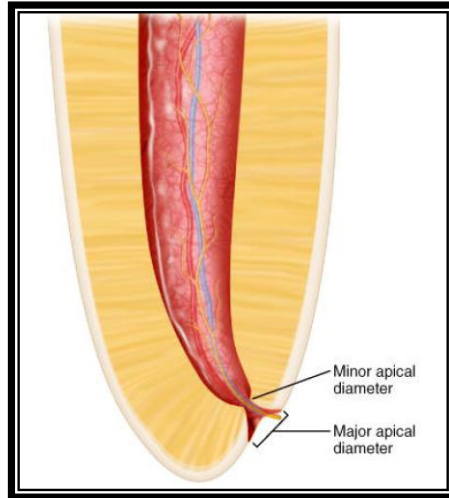
In case of posterior teeth, ex: mesial canal, it's so difficult to use barbed broach, so we use a file instead of barbed broach.

The determination of an accurate working length is one of the most critical steps of Endodontic therapy. The cleaning, shaping and obturation of the root canal system cannot be accomplished accurately unless the working length is determined precisely.

Anatomic consideration and terminology:-

- ❖ Working length: - the distance from a coronal reference point to the point of which canal preparation and obturation should terminate, the ideal apical reference point in the canal, the "apical stop", so to speak.
- ❖ Anatomic apex: - is the tip or the end of the root determined morphologically, whereas the radiographic apex is the tip or end of the root determined radiographically. Root morphology and radiographic distortion may cause the location of the radiographic apex to vary from the anatomic apex.

- ❖ **Apical foramen**: - is the main apical opening of the root canal. It's frequently eccentrically located away from the anatomic or radiographic apex.
- ❖ **Apical constriction**:- is the apical portion of the root canal having the narrowest diameter. This position may vary but is usually 0.5 to 1.0 mm short of the center of the apical foramen.
- ❖ **Cementodentinal junction**:- is the region where the dentin and cementum are united, the point of which the cemental surface terminates at or near the apex of the tooth. It must be pointed out, however, that the cementodentinal junction is a histologic landmark that cannot be located clinically or radiographically.



Methods of determining working length:-

☒ Ideal method:-

To achieve the highest degree of accuracy in working length determination, a combination of several methods should be used. This is most important in canals for which working length determination is difficult. The most common methods are radiographic methods, digital tactile sense, and electronic methods.

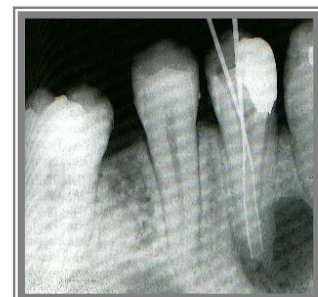
1-Radiographic methods:-

Radiographic method known as the Ingle method has been compared with three other methods of determining working length. The Ingle method proved to be superior to others in the study. It showed a high percentage of success with a smaller variability. This method, first proposed more than 40 years ago, has withstood the test of time and has become the standard as the most commonly used method of radiographic working length estimation.

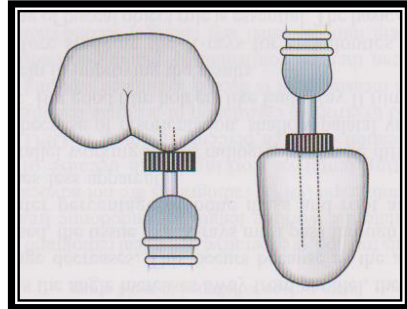
Radiographic Apex Location:-

The following items are essential to perform this procedure:-

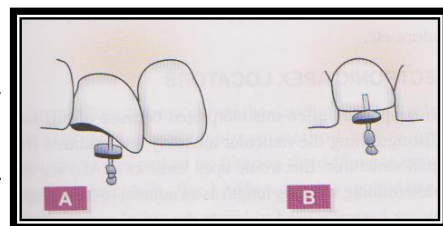
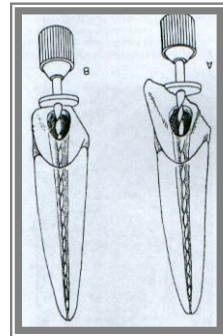
- 1) Good, undistorted, preoperative radiographs showing the total length and all roots of the involved tooth.
- 2) Adequate coronal access to all canals.
- 3) An endodontic millimeter ruler.
- 4) Working knowledge of the average length of all teeth.
- 5) A definite, repeatable plane of reference to an anatomic landmark on the tooth, a fact that should be noted on the patient's record.



Reference point:- is the site on the occlusal or incisal surface from which measurements are made. This point is used through out canal preparation and obturation. A reference point that will easily visualize during preparation is chosen. Usually this is the highest point on the incisal edge on the anterior teeth and a buccal cusp tip on posterior teeth.



It is imperative that teeth with fractured cusps or cusps severely weakened by caries or restoration be reduced to a flattened surface, supported by dentin. Failure to do so may result in cusps or weak enamel walls being fractured between appointments. Thus, the original site of reference is lost. If this fracture goes unobserved, there is the probability of over instrumentation and overfilling, particularly when anesthesia is used. To establish the length of the tooth, a stainless steel reamer or file with an instrument stop on the shaft is needed. The exploring instrument size must be small enough to negotiate the total length of the canal but large enough not to be loose in the canal. A loose instrument may move in or out of the canal after the radiograph and cause serious error in determining the length of tooth.

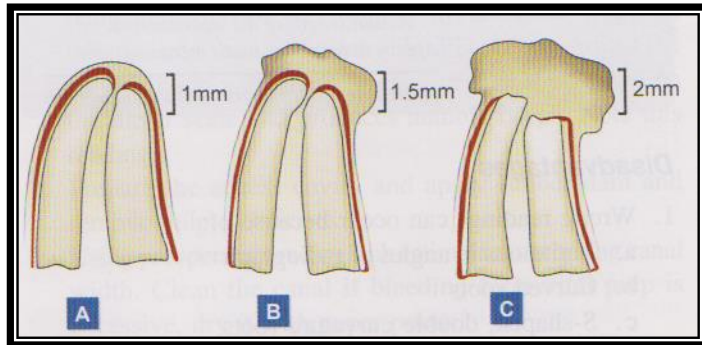


Method:-

- 1- Measure the tooth on the preoperative radiograph (initial measurement).
- 2- Subtract at least 1.0 mm "safety allowance" for possible image distortion or magnification.
- 3- Set the endodontic ruler at this tentative working length and adjust the stop on the instrument at that level.
- 4- Place the instrument in the canal until the stop is at the plane of reference unless pain is felt, in which case, the instrument is felt at level and the rubber stop readjusted to this new point of reference.
- 5- Expose, develop, and clear the radiograph.
- 6- On the radiograph, measure the difference between the end of the instrument and the end of the root and add this amount to the original measured length the instrument extended into the tooth. If, through some oversight, the exploring instrument has gone beyond the apex, subtract this difference.

7- From this adjusted length of tooth, subtract a 1.0 mm "safety factor" to conform to the apical termination of the root canal at the apical constriction.

If, radiographically, there is no resorption of the root end or bone, shorten the length by the standard 1.0mm. If periapical bone resorption is apparent, shorten by 1.5mm, and if both root and bone resorption is apparent, shorten by 2.0 mm. The reasoning behind this suggestion is thoughtful. If there is root resorption, the apical constriction is probably destroyed, hence the shorter move backup the canal. Also, when bone resorption is apparent, there probably is also root resorption, even though it may not be apparent radiographically.



8- Set the endodontic ruler at this new corrected length and readjust the stop on the exploring instrument.

2-Digital Tactile Sense:-

If the coronal portion of the canal is not constricted, an experienced clinician may detect an increase in resistance as the file approaches the apical 2 to 3mm. This detection is by tactile sense. In this region, the canal frequently constricts before exiting the root. There is also a tendency for the canal to deviate from the radiographic apex in this region.

The accuracy of just 64% using digital tactile sense. Another study found that the exact position of the apical constriction could be located accurately by tactile sense in only 25% of canals in their study.

All clinicians should be aware that this method, by itself, is often inexact. It is ineffective in root canals with an immature apex and is highly inaccurate if the canal is constricted throughout its entire length or if the canal has excessive curvature. This method should be considered supplementary to high-quality, carefully aligned, parallel, working length radiographs and/or an apex locator.

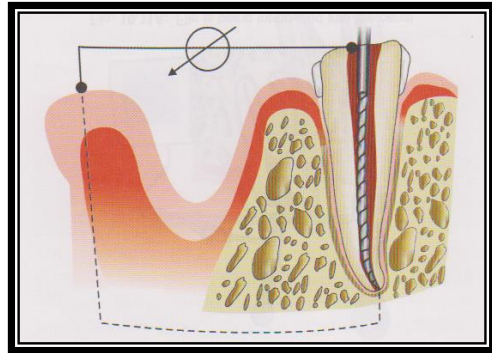
A survey found that few general practice dentists and no endodontists trust the digital tactile method of determining working length by itself. Even the most experienced specialist would be prudent to use two or more methods to determine accurate working lengths in every canal.

3-Determination of Working Length by Electronics:-

Electronic devices have been designed to determine canal length by "reading" when vital tissue has been reached by the file tip at the apical foramen. The electronic principle is relatively simple and is based on

electrical resistance. In 1918, Custer was the first to report the use of electric current to determine working length. The research on dogs using direct current discovered that the electrical resistance between the periodontal ligament and the oral mucosa was a constant value of 6.5 Kilo-ohms. They used a simple direct current ohmmeter to measure a constant resistance of 6.5 kilo-ohms between oral mucous membrane and the periodontium regardless of the size or shape of the teeth. The device used became the basis for most apex locators. The principle is based on the electrical resistance of different tissues. When the circuit is complete, resistance decreases and current begins to flow.

All apex locators function by using the human body to complete an electrical circuit. One side of the apex locator's circuitry is connected to an endodontic instrument. The other side is connected to the patient's body, either by a contact to the patient's lip or by an electrode held in the patient's hand. The electrical circuit is complete when the endodontic instrument is advanced apically inside the root canal until it touches periodontal tissue. The display on the apex locator indicates that the apical area has been reached. According to the device, this event is signaled by a beep, a buzz, flashing light, digital readouts, or a pointer on a dial.



Old types were affected by the presence of saliva, blood inside the canal while recent types are not affected by them and work efficiently in their presence. As recent types depend on the electrical impedance which is the different electric resistance between the cervical and apical dentin.

Uses of apex locators:

1-They are useful in conditions where apical portion of canal system is obstructed by:

a-impacted teeth, b-zygomatic arch, c-excessive bone density, d-tori, e-overlapping roots, f-shallow palatal vault.

In such cases, they can provide information which radiographs cannot.

2-They are useful in patient who cannot tolerate X-ray film placement because of gag reflex.


3-In case of pregnant patients, to reduce the radiation exposure, they can be valuable tool.

4-They can also be used in children who may not tolerate taking radiographs, disabled patients and patients who are heavily sedated.

5-They are helpful in root canal treatment of teeth with incomplete root formation, requiring apexification and to determine working length in primary tooth.

Contraindications:-

The use of apex locators and other electrical devices such as pulp testers, electrosurgical instruments and desensitizing equipment, is contraindicated for patients who have cardiac pacemakers. Electrical stimulation to the pacemaker patient can interfere with pacemaker function. The severity of the interference depends on the specific type of pacemaker and the patient's dependence on it. In special cases, an apex locator may be used on a patient with a pacemaker when it's done in close consultation with the patient's cardiologist.



Thank you